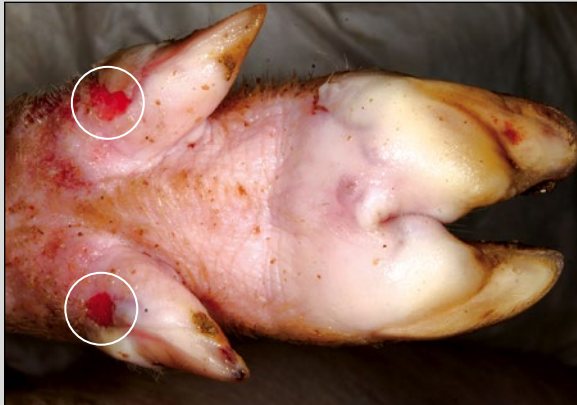

# FOOT AND MOUTH DISEASE IN PIGS

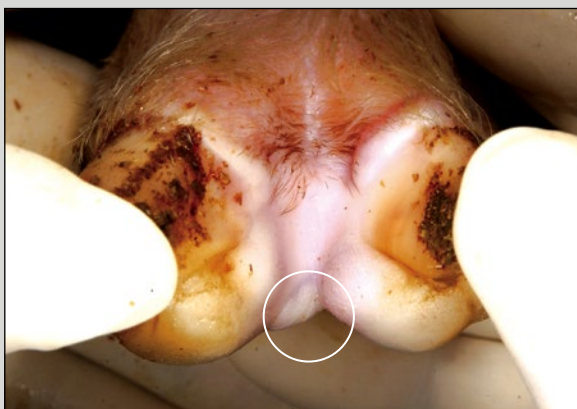
## PROGRESSION OF LESIONS POST-INFECTION

Foot and mouth disease (FMD) is a highly contagious viral disease of pigs. Signs of illness are similar to other swine diseases such as Senecavirus.

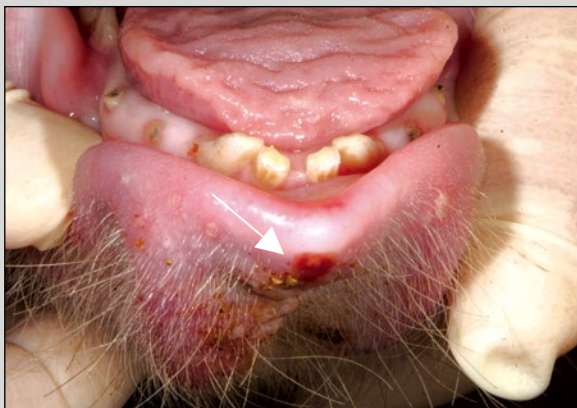
**DAY 2**



Vesicles of hoof pads and ruptured vesicles of dewclaws

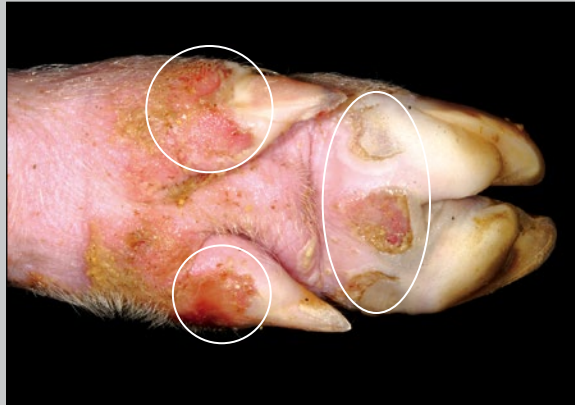

Vesicle in interdigital area

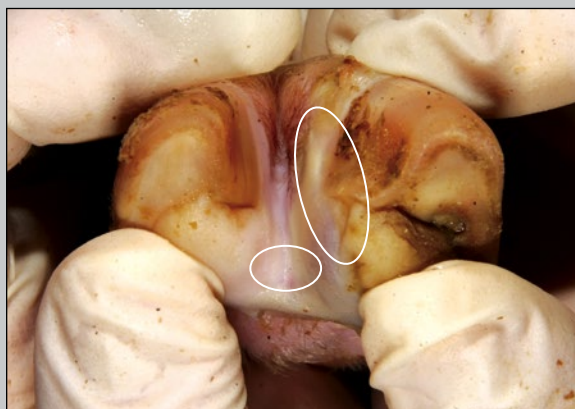

Erosion of tip of lower lip

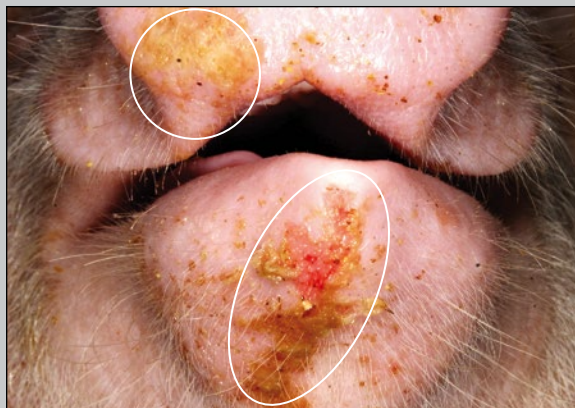**DAY 4**



Ulcerations and erosions from ruptured vesicles

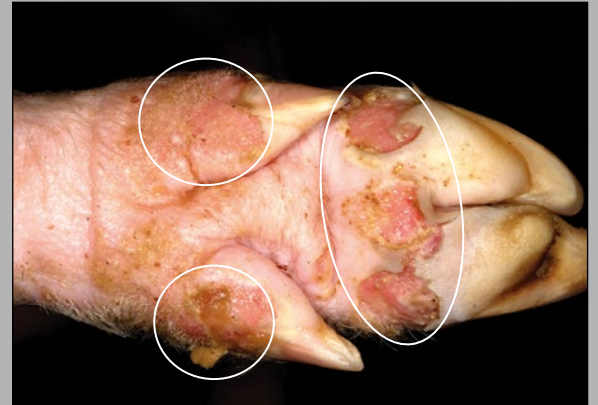

Vesicle in interdigital area and swollen coronary band

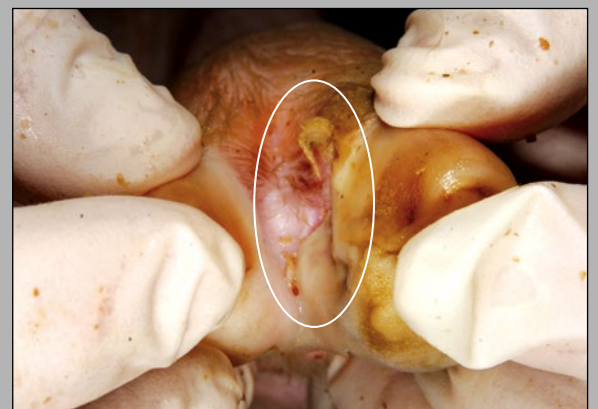


Erosion of lower lip and snout with fibrin

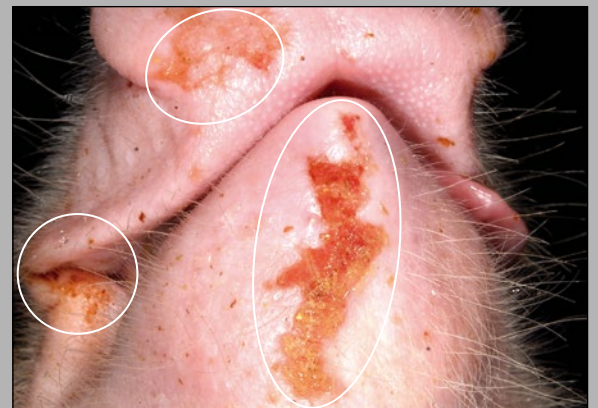**DAY 6**



Multifocal deep ulcers, hoof pad and dewclaws at the coronary band

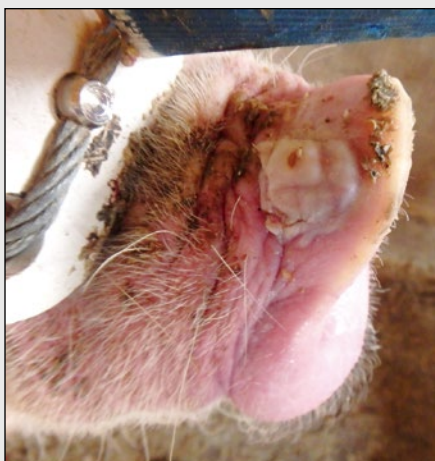

Interdigital ulceration at coronary band

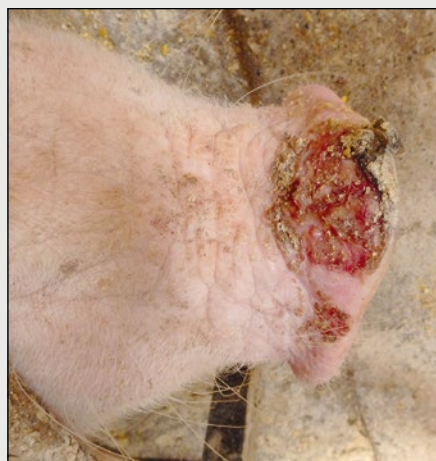

Erosion with fibrin deposition

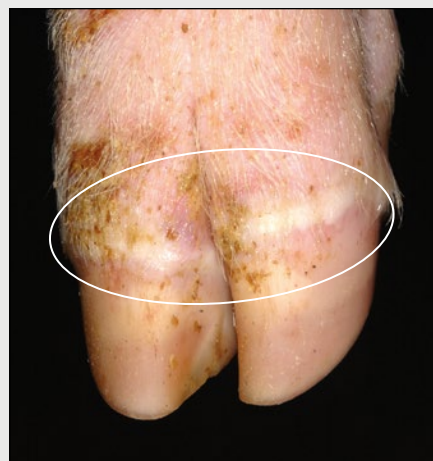### OTHER PRESENTATIONS YOU MIGHT SEE



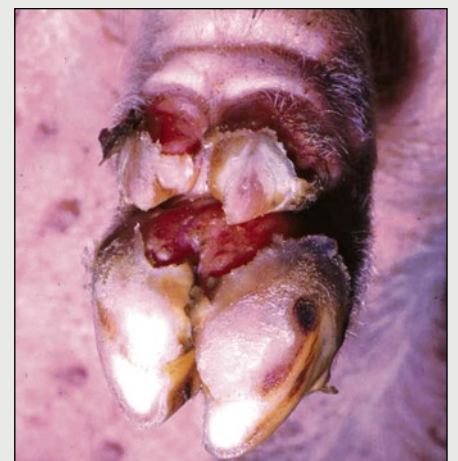Vesicular lesions on the snout



Large erosion on the snout



Blanching of the coronary band



Sloughing of claw

### IF YOU SUSPECT A FOREIGN ANIMAL DISEASE:

Call your herd veterinarian, State Animal Health Official (SAHO), or Area Veterinarian-In-Charge (AVIC) to report your concerns, or call 1-866-536-7593 or 800-940-6524 (24 hours) to reach USDA APHIS Veterinary Services for assistance.

Photo Credit: USDA APHIS Foreign Animal Disease Diagnostic Laboratory, Department of Homeland Security Visual Information Service at Plum Island Animal Disease Center, and the Swine Medicine Education Center



United States Department of Agriculture (USDA)  
Animal and Plant Health Inspection Service, Veterinary Services  
4700 River Road  
Riverdale, MD 20737  
aphis.usda.gov



American Association of Swine Veterinarians (AASV)  
830 26th Street  
Perry, IA 50220  
aasv.org  
515-465-5255



National Pork Board  
1776 NW 114th Street  
Des Moines, IA 50325  
porkcheckoff.org  
800-456-7675



Center for Food Security and Public Health (CFSPH)  
College of Veterinary Medicine  
Iowa State University  
Ames, IA 50011  
cfsph.iastate.edu